

CME

Follow the link from the online version of this article to obtain certified continuing medical education credits

# Achilles tendon disorders

Chad A Asplund,<sup>1</sup> Thomas M Best<sup>2</sup>

<sup>1</sup>Department of Family Medicine, Eisenhower Army Medical Center, Fort Gordon, GA 30905, USA

<sup>2</sup>Division of Sports Medicine, Department of Family Medicine, Ohio State University, Columbus, OH 43221, USA

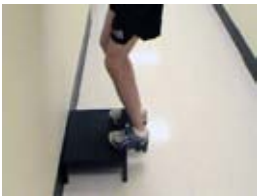Correspondence to: C A Asplund  
chad.asplund@gmail.com

Cite this as: *BMJ* 2013;346:f1262

doi: 10.1136/bmj.f1262

[bmj.com/multimedia](http://bmj.com/multimedia)

Watch a video demonstration of eccentric calf exercises



Disorders of the Achilles tendon are common in active people—competitive and recreational athletes alike—but they can occur in less active people. As the largest tendon in the body, the Achilles experiences repetitive strain from running, jumping, and sudden acceleration or deceleration, so is susceptible to rupture and degenerative changes. This review aims to describe the anatomy and diagnostic evaluation of the Achilles tendon, and to discuss the best available evidence to help in the management of Achilles tendon disorders.

## What are Achilles tendon disorders?

The Achilles tendon is the strongest tendon in the body,<sup>1</sup> serving both the gastrocnemius and soleus muscles. It begins near the mid-calf and inserts posteriorly at the calcaneus (fig 1). In the region where the tendon joins the bone, there is an amalgam called the enthesis organ, in which the tissue is a composite of bone and tendon.<sup>2</sup> Kager's fat pad is located anterior to the Achilles tendon and posterior to the calcaneus, forms the superior border of this enthesis organ, and protects the blood vessels of the Achilles tendon.<sup>2</sup> The fat pad may also provide a mechanical advantage by increasing the lever angle of the Achilles tendon during plantar flexion.<sup>3</sup> Unlike other tendons, the

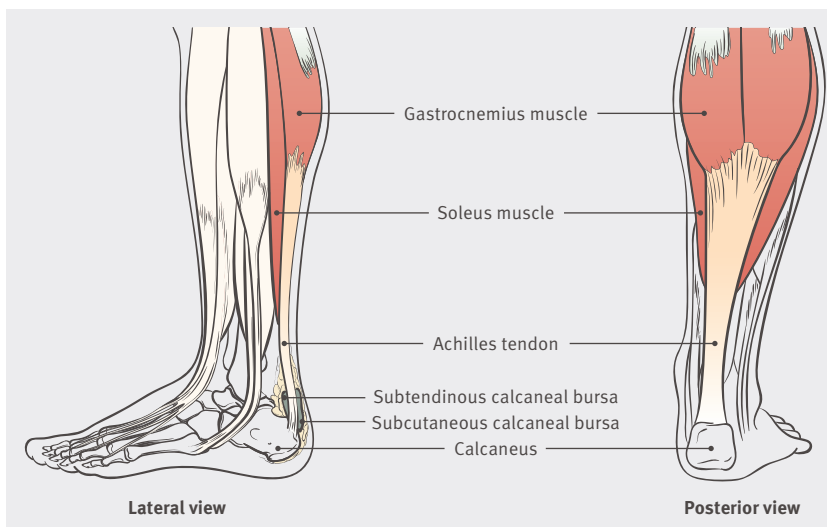


Fig 1 | Anatomy of the Achilles tendon

## SOURCES AND SELECTION CRITERIA

We searched Medline (to include the Cochrane database) with the terms tendinopathy, Achilles tendon, tendon injuries, and Achilles tendon disorders. This was further limited to Achilles and finally to English language, human subjects within the past five years, and randomized controlled trials or evidence based reviews. The search yielded 70 references. We reviewed the abstracts of these 70 references and 57 met the inclusion criteria. Further landmark studies were added.

Achilles does not have a true synovial sheath but has a paratenon, which is a sheath of flexible connective tissue that allows for a gliding action. The paratenon and Achilles tendon are innervated by nerves from attached muscles and small fasciculi from cutaneous nerves, especially the sural nerve.<sup>4</sup> The paratenon is a highly vascular structure, and along with the surrounding muscle complex supplies blood to the Achilles tendon.<sup>5</sup>

Cadaveric studies suggest that there is an area 2-6 cm above the calcaneal insertion with a relatively poor blood supply, and that this predisposes the region to chronic inflammation and rupture.<sup>5-6</sup> However, in vivo studies have failed to demonstrate this “watershed” area. Direct measurement of forces reveal loading in the Achilles tendon to be as high as 9 kilonewtons (up to 12.5 times body weight) during running, which probably contributes to its high rate of injury.<sup>7</sup>

Tendinitis is a common term used with Achilles disorders. However, chronic overuse tendon injuries are not caused by inflammation—instead, histology typically shows tissue degeneration and disorganization.<sup>8</sup> Tendinopathy or tendinosis are therefore more accurate terms, with tendinopathy the clinical term and tendinosis its pathological equivalent.

Recently, it has been proposed that tendon injury occurs along a continuum.<sup>9</sup> Initially, reactive tendinopathy is caused by overload. This results in a non-inflammatory response that thickens the tendon, reduces stress, and increases stiffness in response to overload. If overload continues, this leads to tendon dysrepair and highly disorganized tissue and, finally, degenerative tendinopathy, with even greater cellular disorder.<sup>9</sup> It is unclear if this degeneration within the tendon is the source of pain because many asymptomatic tendons show degenerative changes.<sup>10</sup> Painful tendons, however, show an increase in sensory and sympathetic nerves from the highly innervated paratenon and fat pad,<sup>11</sup> which may be the source of pain in symptomatic tendinopathy.

## Who gets Achilles tendon disorders?

Achilles tendinopathy generally occurs in the midsubstance of the tendon or less commonly at its insertion in the calcaneus; this differentiation is important because

## SUMMARY POINTS

Midsubstance Achilles tendinopathy is more common than the insertional variant  
Rupture is most common in men in the fourth and fifth decades of life  
Eccentric exercises are the best treatment for Achilles tendinopathy  
Other modalities such as shock wave therapy are additive to eccentric exercises in the treatment of recalcitrant Achilles tendinopathy  
Early weight bearing and progressive rehabilitation improve outcomes for the non-operative management of Achilles tendon rupture

**bmj.com**

Previous articles in this series

- ▶ Malignant and premalignant lesions of the penis (BMJ 2013;346:f1149)
- ▶ Postpartum management of hypertension (BMJ 2013;346:f894)
- ▶ Diagnosis and management of pulmonary embolism (BMJ 2013;346:f757)
- ▶ Anaphylaxis: the acute episode and beyond (BMJ 2013;346:f602)
- ▶ Ulcerative colitis (BMJ 2013;346:f432)
- ▶ Prostate cancer screening and the management of clinically localized disease (BMJ 2013;346:f325)

the treatments differ. Tendon rupture can be complete or partial and the treatments for both of these will also be discussed.

**Tendinopathy**

The most common causes of Achilles disorders are mid-substance tendinopathy (55-65%), followed by insertional tendinopathy (20-25%).<sup>12</sup> Achilles tendon disorders can affect anyone, but they most commonly affect active people, especially those who participate in running or jumping sports. In a cohort study with an 11 year follow-up, Achilles tendon overuse injuries occurred in 29% of runners compared with 4% of non-runners; the age adjusted odds ratio was 10.0 in runners compared with controls.<sup>13</sup>

Age, male sex, and obesity have been cited as risk factors for Achilles tendon disorders, but a recent study of athletes over 40 years of age found no influence of any of these factors.<sup>14 15</sup> A study of military recruits found that decreased plantar flexion strength and extremes of dorsiflexion (too much or too little) were associated with Achilles disorders.<sup>16</sup> Abnormal subtalar joint motion has also been found to contribute to midsubstance tendinopathy.<sup>17</sup> A positive family history raises the risk of Achilles tendinopathy almost five times, suggesting a possible genetic link.<sup>15</sup> Medical factors that may be associated with Achilles injury include hypertension, hyperlipidemia, and diabetes—presumably secondary to glycation or systemic inflammation.<sup>18</sup>

**Tendon rupture**

It is now recognized that most tendinopathies are rarely associated with one single factor, and the degenerative process that precedes rupture likely results from a variety of different pathways and causative factors. Degenerative changes are likely over age 35 years and contribute to the increased susceptibility to tendon rupture.<sup>10</sup> Achilles tendon ruptures are most common in men in the fourth to fifth decade of life, perhaps because degenerative changes have started but activity levels are still high.<sup>19</sup> The incidence of Achilles tendon rupture is seven injuries per 100 000 in the general population and 12 injuries per 100 000 in competitive athletes.<sup>19</sup> Finally, a history of Achilles rupture places the person at a higher risk of injury to the contralateral Achilles.<sup>20</sup> Running, jumping, or sudden explosive or eccentric activities are the usual mechanisms for rupture.<sup>21</sup>

Drugs may be associated with Achilles rupture in less active older adults. A population based cohort study found that fluoroquinolone antibiotics are associated with 12 episodes of rupture per 100 000 treatment episodes.<sup>22</sup> Another population based drug safety study found that use of fluoroquinolones increased risk for tendon disorders (odds ratio 1.7, 95% confidence interval 1.4 to 2.0) and Achilles rupture (4.1, 1.8 to 9.6), whereas concomitant use of fluoroquinolones and oral corticosteroids significantly increased the risk of Achilles rupture (43.2, 5.5 to 341.1).<sup>23</sup>

**How are Achilles tendon disorders evaluated?**

A thorough history and physical examination are the first steps in the diagnosis of Achilles tendon disorders. The history should include pattern of symptoms—onset, dura-

**A PATIENT'S PERSPECTIVE**

I am a 39 year old competitive runner. When running on the beach while on vacation I suddenly felt a burning pain in my left mid-calf. This was followed by a sudden pop and I was unable to finish the run. Examination showed ecchymosis and a small palpable defect in the lateral border of the left Achilles tendon near the myotendinous junction with a negative calf squeeze test. Magnetic resonance imaging demonstrated a 45-50% tear of the Achilles tendon at the myotendinous junction. After an initial period of limited weight bearing, ice, and compression, I underwent an ultrasound guided platelet rich plasma injection. I was placed in a walking boot for six weeks followed by a progressive rehabilitation eccentric exercise program. Four months after the initial injury, I have started running again.

tion, cessation, plus alleviating and exacerbating factors. Ascertain the level of training, previous injury, and previous treatments. Also determine the presence of risk factors, such as previous injury, family history, medical history, and drug use.

**Tendinopathy**

Patients with tendinopathy generally describe pain or stiffness in the Achilles 2-6 cm above the calcaneal insertion.<sup>24</sup> Morning stiffness is common, and the pain is usually worse with activity, although it may continue into rest. Less commonly, patients will describe similar symptoms with point tenderness over the insertion of the Achilles on the calcaneus.

Inspection of the patient's gait may elicit the presence of overt gait abnormalities. With the patient in a prone position, palpate the distal lower leg to assess areas of tenderness. Tenderness in the body of the tendon or directly over the insertion, with or without crepitus, suggests tendinopathy. Swelling around the tendon or crepitus with active motion may indicate inflammation of the paratenon. Tendinopathy and paratendinopathy may coexist.<sup>25</sup> In isolated paratendinopathy, there is local thickening of the paratenon. Finally, assess range of motion (passive and active) and strength testing to plantar flexion, dorsiflexion, eversion, and inversion, along with subtalar mobility to evaluate for restrictions to motion or muscle weakness, which would predispose to re-injury. It is essential to compare the injured limb with the contralateral non-injured limb to appreciate subtle differences.

Severity of tendinopathy, as well as response to treatment, can be assessed by using a validated outcome measure such as the Victorian Institute of Sport assessment (VISA-A), which consists of eight items to assess stiffness, pain, and function.<sup>26</sup>

**Rupture**

Classically patients with complete tendon rupture will describe the feeling of "being shot or hit in the back of the leg," typically while performing an explosive running or jumping maneuver, with immediate pain and an inability to continue their current activity.

Because gravity and activity of the tibialis posterior, peroneals, and long toe flexors can cause active plantar flexion, examine patients for suspected rupture while they are prone. Ecchymosis suggests tendon rupture, and a

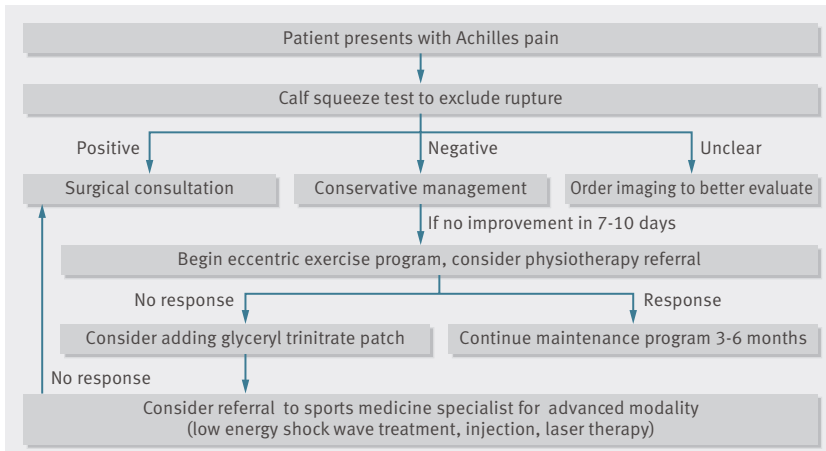


Fig 2 | Algorithm for the treatment of Achilles tendon disorders

### ADDITIONAL EDUCATIONAL RESOURCES

#### Resources for healthcare professionals

American Academy of Orthopaedic Surgeons. The diagnosis and treatment of acute Achilles tendon rupture: guideline and evidence report. 2009. [www.aaos.org/research/guidelines/atrguideline.pdf](http://www.aaos.org/research/guidelines/atrguideline.pdf)

Carcia CR, Martin RL, Houck J, Wukich DK. Achilles pain, stiffness, and muscle power deficits: Achilles tendinitis clinical practice guidelines linked to the international classification of functioning, disability, and health from the orthopaedic section of the American Physical Therapy Association. *J Orthop Sports Phys Ther* 2010;40:A1-26.

Maffulli N, Almekinders LC. *The Achilles tendon*. Springer, 2007

Alfredson H, Cook J. A treatment algorithm for managing Achilles tendinopathy: new treatment options. *Br J Sports Med* 2007;41:211-6

#### Resources for patients

Kreher JB. Achilles tendinopathy: everything you need to know (and more). What you should know about Achilles tendinopathy to prevent its occurrence and to stop it in its tracks before it stops you. [www.beginnertriathlete.com/cms/article-detail.asp?articleid=1694](http://www.beginnertriathlete.com/cms/article-detail.asp?articleid=1694)

Beginnertriathlete.com ([www.beginnertriathlete.com/cms/article-detail.asp?articleid=1313](http://www.beginnertriathlete.com/cms/article-detail.asp?articleid=1313))—Video case study on Achilles tendonitis

palpable defect may exist within the first hours of rupture. Tendon rupture can be confirmed with the calf squeeze test, where the examiner gently squeezes the patient's calf muscles with the palm of the hand—if the tendon is intact, plantar flexion will occur, if torn the ankle will remain still. Test both legs to assess for differences. Sensitivity and specificity of this test have been measured at 0.96 (0.91 to 0.99) and 0.93 (0.76 to 0.99), respectively.<sup>27-29</sup>

#### What is the differential diagnosis of posterior heel pain?

Posterior heel pain can be a diagnostic challenge—consider Achilles tendinopathy (midsubstance or insertional) and tendon rupture (partial or complete). Achilles disorders will localize pain to the Achilles tendon, typically along its course from the insertion on the heel to its transition into the conjoined tendon of the gastrocnemius and soleus. However, differential diagnoses include retrocalcaneal bursitis or enthesitis, plantaris muscle injury, posterior ankle impingement, and sural nerve impingement or entrapment.

Retrocalcaneal bursitis may occur near the distal insertion of the Achilles and may mimic insertional tendinopathy, and both disorders can occur simultaneously. In Achilles enthesitis, in addition to the tendon findings, an

effusion is often present in the retrocalcaneal bursa. This condition can be investigated using three finger palpation. The middle finger and thumb are placed on each side of the Achilles while the index finger palpates the distal tendon; fluctuation palpated with the index finger can indicate effusion of the retrocalcaneal bursa.<sup>30</sup> The plantaris muscle is a vestigial rope-like structure seen in 7-20% of the population.<sup>31</sup> It lies deep to the proximal lateral gastrocnemius muscle, travels obliquely, and inserts near the medial border of the Achilles tendon; in some cases it fuses with the Achilles.<sup>32</sup> Injury to the plantaris can mimic the symptoms seen with Achilles tendon disorders and can be diagnosed with magnetic resonance imaging (MRI) or ultrasound.<sup>33 34</sup> Posterior impingement of the ankle refers to impingement of the posterior talus by the posterior aspect of the tibia when the ankle is in extreme plantar flexion. In this condition, pain occurs in the posterior ankle but increases with passive plantar flexion of the ankle, unlike in Achilles tendinopathy, in which the pain lessens. Finally, sural nerve entrapment or impingement may cause pain in the posterior distal leg and may mimic Achilles pathology.

#### What is the role of imaging in Achilles tendon disorders?

Most Achilles disorders are diagnosed clinically. Imaging may be useful, however, when the diagnosis is unclear or when trying to differentiate between complete or partial tendon rupture. Ultrasound and MRI are useful when clinical examination does not yield a definitive diagnosis.

MRI is useful in the diagnosis of tendon disorders because it can detect abnormalities in the entire locomotor unit, including the tendon, calcaneus, Achilles insertion, retrocalcaneal bursa, peritendinous tissues, and musculo-tendinous junction. MRI findings also correlate with findings at surgery and may be useful for surgical planning.<sup>35</sup>

Ultrasound, however, can provide a dynamic assessment of the tendon and can evaluate for tissue neovascularization. Perhaps more importantly, it can be used to guide percutaneous procedures and is therefore becoming a popular imaging tool. In a prospective blinded comparison study of ultrasound and MRI for identification of Achilles tendinopathy, both had similar specificity, but MRI had better sensitivity (95% v 80%).<sup>36</sup> However, a recent retrospective study comparing MRI with physical examination found that MRI was less sensitive in the diagnosis of Achilles tendon rupture and may be useful only for operative planning.<sup>37</sup> In a prospective longitudinal cohort study, ultrasound was used to measure neovascularization before and after eccentric exercises to help predict patient outcome, with a decrease in neovascularity corresponding to patient improvement.<sup>38</sup> It has been suggested that, in trained hands, ultrasound is better for focused examinations or for guiding intervention, whereas MRI is better for global assessment of the tendon or for operative planning.<sup>39</sup>

#### What are the treatment options?

Figure 2 shows an algorithm for the treatment of Achilles tendon disorders. Consider conservative treatment first for most Achilles tendon disorders. The aims of treatment are load reduction and pain management. Advise patients with tendinopathy to reduce or discontinue the offending activity, weight bear as tolerated, use a heel lift to effectively

shorten the Achilles and reduce load, and use acetaminophen (paracetamol) as needed for pain. Refer patients with complete rupture to a surgeon for advice about treatment options. Additional treatments for specific Achilles tendon disorders are outlined below. If conservative measures fail, refer to a sports medicine or orthopaedic specialist.

#### Midsubstance Achilles tendinopathy

Eccentric calf exercises have the most evidence and best outcomes for the treatment of midsubstance Achilles tendinopathy. A meta-analysis of 11 randomised controlled trials (RCTs) found that eccentric exercises improved pain, patient function, and satisfaction compared with control treatments, such as concentric exercises, stretching, splinting, and ultrasound.<sup>40</sup> Another systematic review of 16 RCTs of non-operative treatments for midportion Achilles tendinopathy found that eccentric exercises had the most evidence of effectiveness.<sup>41</sup> Furthermore, a five year follow-up study of an RCT found sustained long term improvement with eccentric exercises performed according to Alfredson's heel drop program.<sup>42</sup> Currently, we recommend Alfredson's method of performing three sets of 15 repetitions, twice a day, every day for up to 12 weeks (see video).<sup>43</sup>

Does the addition of other treatments to eccentric exercises improve results? Two RCTs found that the addition of low energy shock wave treatment to eccentric exercises is more effective than eccentric exercise alone.<sup>44 45</sup> Finally, the addition of low level laser therapy to eccentric exercises accelerated clinical recovery.<sup>46</sup> Therefore both of these treatments may be additive to eccentric exercise and may be useful in patients who do not respond to the initial eccentric exercises.

Topical glyceryl trinitrate has been used to treat tendinopathies, but is it effective for Achilles tendinopathy? A meta-analysis of seven studies showed that glyceryl trinitrate reduces pain during activities of daily living in chronic tendinopathies, with an odds ratio of 4.44 (2.34 to 8.40), and in acute and chronic phases combined, with an odds ratio of 4.86 (2.62 to 9.02).<sup>47</sup> For the specific treatment of Achilles tendinopathy, another systematic review found two RCTs of topical glyceryl trinitrate alone in the treatment of chronic (more than six weeks) Achilles tendinopathy. One trial found a benefit of glyceryl trinitrate in terms of pain on activity or at night and tendon tenderness, but the other trial found no difference from placebo at six months on pain at rest or with activity.<sup>47</sup> Finally, another RCT comparing physical therapy plus topical glyceryl trinitrate with therapy alone found that addition of glyceryl trinitrate was of questionable benefit.<sup>48</sup> Despite evidence at the cellular level of the role of nitric oxide in tendon healing, results of clinical studies in human Achilles tendons have been conflicting, so further validation is needed. If glyceryl trinitrate is used, we recommend cutting a 5 mg 24 hour patch into four and placing one quarter over the area of maximal tenderness or pain. Leave the patch in place for 24 hours and then replace the patch daily until pain subsides or 12 weeks of treatment have been completed, when patient centered outcomes such as pain and function should be re-evaluated.

#### Insertional tendinopathy

Much of the evidence is for the treatment of midsubstance tendinopathy, and it is unclear if it directly translates to treatment of insertional tendinopathy. A systematic review of 11 studies concluded that conservative treatment, including eccentric loading exercises and shock wave therapy, should be attempted before operative intervention.<sup>49</sup> A small pilot study to evaluate the effect of painful eccentric loading exercises without dorsiflexion (different from eccentric loading exercises for midsubstance tendinopathy) found that two thirds of the patients who performed such exercises improved clinically. Interestingly, combined disease (such as tendon, bursa, or enthesitis) at the insertion does not exclude a satisfactory response to this training regimen.<sup>50</sup> Finally, a larger RCT of people with chronic insertional tendinopathy found that low energy shock wave therapy may be superior to eccentric loading exercises in improving functional outcome scores.<sup>51</sup> This treatment may be useful in patients with a poor initial response to eccentric loading exercises.

#### Achilles rupture

##### *Complete rupture*

Surgery is often recommended for complete Achilles rupture, but there is some controversy about its long term effectiveness. A meta-analysis of six RCTs comparing minimally invasive surgery with conventional approaches found no significant difference in outcomes, although minimally invasive surgery resulted in fewer infections and greater patient satisfaction.<sup>52</sup> In a Cochrane systematic review, open surgery was associated with a much lower rate of re-rupture than conservative treatment but had a higher rate of complications.<sup>53</sup> If surgical repair is performed, current evidence supports a minimally invasive technique, and evidence supports early weight bearing to improve functional outcome scores.<sup>54</sup>

Although surgery is generally considered the gold standard, two RCTs comparing surgery to conservative management with immobilization for complete tendon rupture showed no significant difference after one year in functional outcomes.<sup>55 56</sup> Another RCT of operative versus non-operative (accelerated functional rehabilitation program) treatment of Achilles tendon rupture found that all outcome measures, including rate of re-rupture, were similar in both groups.<sup>57</sup> In this study, all patients wore a walking boot with a 2 cm heel lift two weeks after injury; early range of motion and weight bearing as tolerated started at four to six weeks and strength exercises at six to eight weeks. Finally, an RCT of early motion plus surgery versus early motion without surgery suggested that controlled early motion is an important part of treatment for a ruptured Achilles tendon.<sup>58</sup> Therefore, recent studies indicate that good outcomes may be achieved without surgery, especially with accelerated functional rehabilitation and early motion. Maintain a high level of suspicion for deep venous thrombosis, the incidence of which is high after complete rupture.<sup>59</sup>

Because outcomes can be similar for conservative or surgical management, it is useful to know which patients are most suitable for surgery. Non-surgical management is generally best for older less active patients or those with poor skin integrity or wound healing problems.<sup>53</sup> Surgical

**TIPS FOR NON-SPECIALISTS**

Eccentric exercise programs have the best success rate for Achilles tendinopathy  
 Consider surgical referral if no response after six months of conservative treatment or for acute complete rupture of the Achilles tendon

**AREAS FOR FUTURE RESEARCH**

The role of biological agents in the treatment of Achilles tendon disorders  
 The role of ultrasound or advanced imaging techniques as prognostic tools in Achilles disorders

management is recommended for young people, active high level athletes, and those in whom non-surgical management has been unsuccessful.

*Partial rupture*

Much of the research into the treatment of Achilles rupture has been performed on complete tendon rupture rather than partial rupture. It is difficult to differentiate partial tears from tendinopathy. Imaging may help, but MRI findings can overlap substantially.<sup>60</sup> Ultrasound can differentiate full thickness tears from partial thickness ones or tendinosis of the Achilles tendon with 92% accuracy,<sup>36 61</sup> so should be used in this situation.

Tendon repair can be slow and incomplete, and partial tendon ruptures often respond poorly to conservative measures. Surgery has therefore been the recommended treatment,<sup>41</sup> even though it has a long recovery period and greater incidence of complications. Recently, despite the apparent lack of effectiveness of platelet-rich plasma for treating Achilles tendinopathy, two case reports found a

successful return to sports and long term outcome after treatment of a partial Achilles rupture with the injection of platelet-rich plasma followed by a progressive rehabilitation program.<sup>62 63</sup> Platelet-rich plasma may be a useful addition to the current conservative management options for partial Achilles tendon ruptures, although more definitive studies are needed before it can be recommended.

**What is the prognosis?**

Most people who develop Achilles tendinopathy will improve with conservative treatment. In general, significant decreases in pain and improvement in function occur after 12 weeks of intervention.<sup>64</sup> A long term follow-up study showed that 85% of patients with Achilles tendinopathy had full normal function and continued to be asymptomatic eight years after injury.<sup>65</sup> Surgery for tendinopathy is reserved for patients who do not respond after six months of conservative measures. Nevertheless, 24 of the 83 patients in the long term follow-up study did not respond to conservative treatment and underwent surgery.<sup>65</sup>

Treatment of complete Achilles rupture is controversial, but good outcomes have been seen after both operative and non-operative approaches.<sup>55-57</sup> Regardless of treatment approach, functional deficits may persist for up to two years.<sup>66</sup> It is therefore important to advise patients of the potential for a long recovery.

Contributors: CA and TB conceived and designed the article. CA performed the literature search and wrote the initial draft. TB revised this and further drafts. All authors approved the final version. CA is guarantor.

Competing interests: None declared

Provenance and peer review: Commissioned; externally peer reviewed.

Patient consent obtained.

References are in the version on bmj.com.

**ANSWERS TO ENDGAMES, p 40** For long answers go to the Education channel on [bmj.com](http://bmj.com)**STATISTICAL QUESTION****Normal ranges**

Statement *b* is true, whereas *a* and *c* are false.

**PICTURE QUIZ****Peri-oral papules**

- 1 This cluster of papules in a peri-oral distribution is molluscum contagiosum.
- 2 It is unusual to find multiple molluscum lesions on the face of a healthy adult so look for causes of immunocompromise. Investigations should include a full blood count and HIV serology.
- 3 Treatment is not usually needed in children or young adults because molluscum contagiosum resolves spontaneously in most cases. In atypical infections topical imiquimod or cryotherapy can be used.
- 4 Skin disease may be the first sign of HIV infection. Cutaneous infections and skin malignancies are more common in HIV positive patients.

**CASE REPORT****An unexpected finding after a fall from a horse**

- 1 A white blood cell count greater than  $50 \times 10^9/L$  is caused by a primary haematological disease or, less commonly at such a high value, a leukemoid reaction. A leukemoid reaction may be lymphoid or myeloid in nature and is a physiological response of the bone marrow to a strong stimulus, such as infection, drugs, or an underlying solid cancer.
- 2 The chronic phase of chronic myeloid leukaemia (CML).
- 3 In addition to blood count and differential, examination of a blood film and bone marrow biopsy will help to exclude other differential diagnoses, such as other myeloproliferative disorders (polycythaemia rubra vera, essential thrombocytopenia, myelofibrosis) or chronic myelomonocytic leukaemia, and will help determine the stage of CML. Further confirmation can then be obtained using cytogenetics to look for the presence of the Philadelphia chromosome (t(9;22)(q34;q11)) and of the BCR-ABL transcript.
- 4 Treatments include disease control with targeted treatment—the tyrosine kinase inhibitors, such as imatinib—and potential cure with allogeneic haematopoietic stem cell transplantation.
- 5 To reduce the risk of gout and tumour lysis syndrome in response to cytoreductive treatment.